Figures for Chapter 6: Endoscopic and Pathologic Findings, Debora Duro, MD, MS, in Clinical Management of Intestinal Failure, Duggan C, Gura K, Jaksic T (eds), CRC Press, 2011.

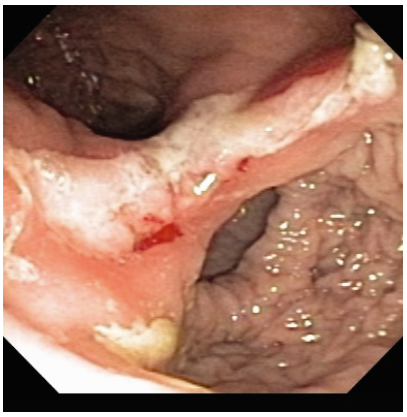

Figure 1a. Anastomotic ulcer at the level of ileocolonic anastomosis in a patient with refractory iron deficiency anemia.

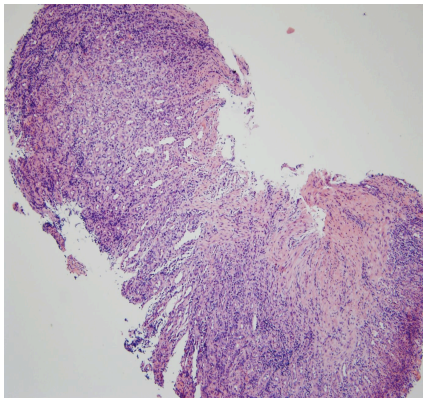

Figure 1b. H & E 10X Anastomosis site showing granulation tissue with dense inflammation and prominent vascular channels.

Figure 2a. Colonoscopy revealed erythema, mucosa friability and focal erosions in this patient with intestinal failure and hematochezia.

Figure 2b. Biopsies confirmed high eosinophil count throughout his colonic mucosa.

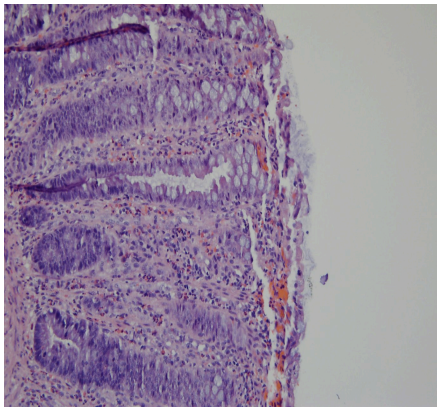

Figure 2c. Figure 2 H & E 40 X Colonic mucosa with a markedly increased number of eosinophils in the lamina propria.

Figure 3a. Esophagus showing pale mucosa and linear furrows in a patient with intestinal failure who presented with vomiting.

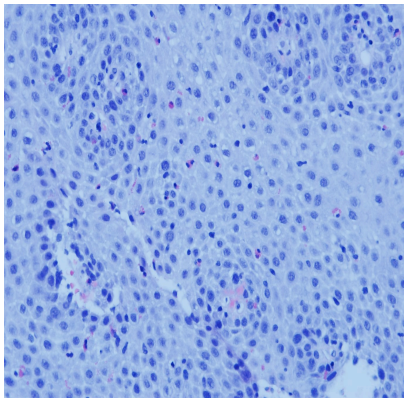

Figure 3b. H & E 40X Histologic findings confirmed the presence of eosinophilic esophagitis (> 15 eosinophils per high-powered field).

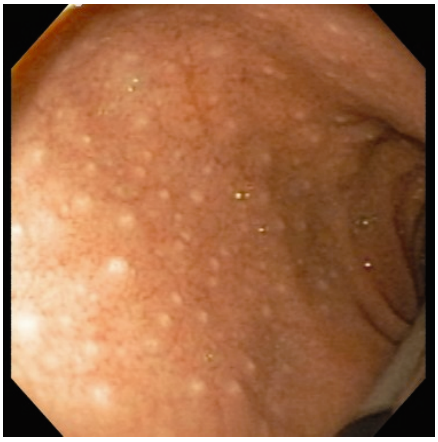

Figure 4a. Duodenal bulb showing granular and nodular pattern, with biopsies in this area demonstrating villous atrophy, increased intraepithelial lymphocytes and mild villous blunting.

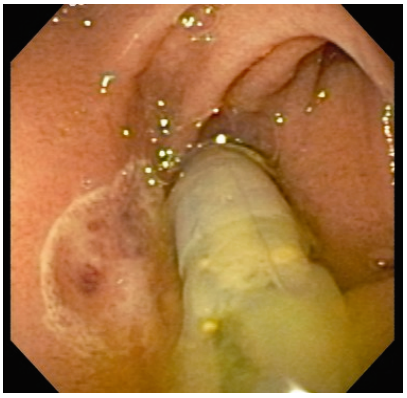

Figure 4b. Second portion of duodenum showed a small ulcer adjacent to the gastro-jejunostomy feeding tube. Biopsies demonstrated focal duodenitis.

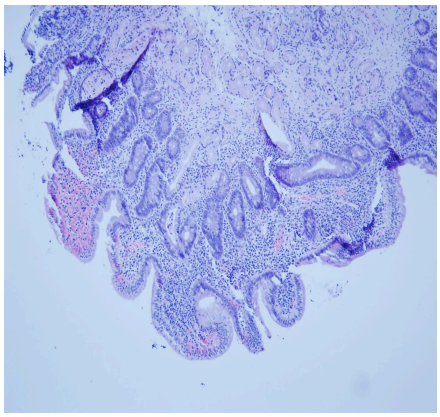

Figure 4c. H & E 40X Duodenal mucosa with villous atrophy, crypt hyperplasia, and intraepithelial lymphocytosis.

Figure 5a. Ileoscopy demonstrating multiple small ulcers in a patient with recurrent ostomy bleeding. Biopsy demonstrated chronic inflammatory changes compatible with bacterial overgrowth.

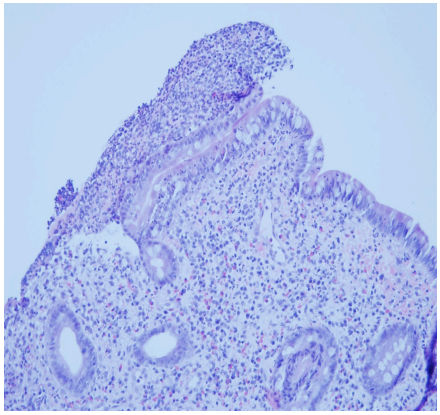

Figure 5b. H & E 20X Small intestinal mucosa with ulceration and superficial neutrophilic exudate.

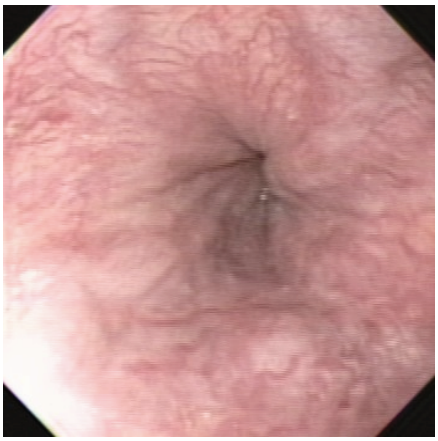

Figure 6a. Esophagitis in a child with IF who chief complaint was chest pain.

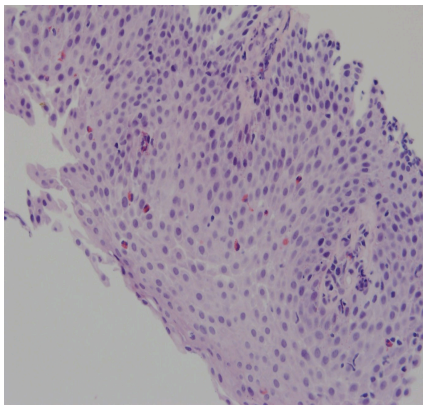

Figure 6b. H & E 40X Squamous epithelium with scattered intraepithelial eosinophils.

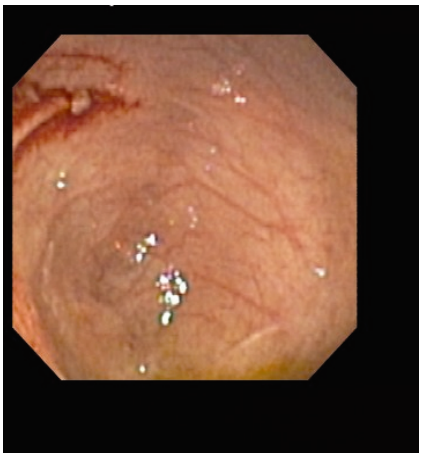

Figure 7. Endoscopy of a duodenal pouch confirmed by upper gastrointestinal series which demonstrated a duodenal web.

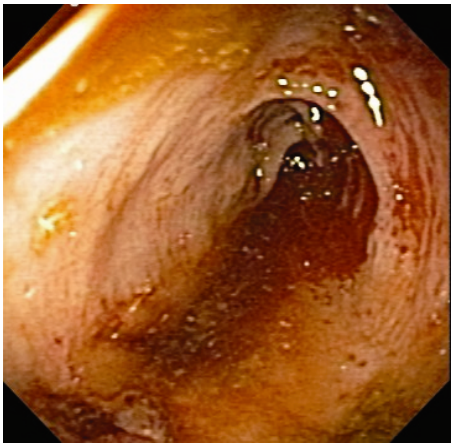

Figure 8. Colonic stricture.

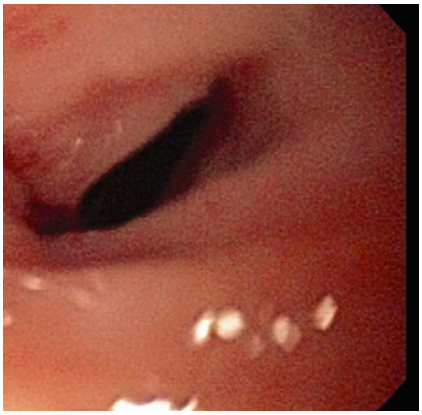

Figure 9. Ileal stricture.

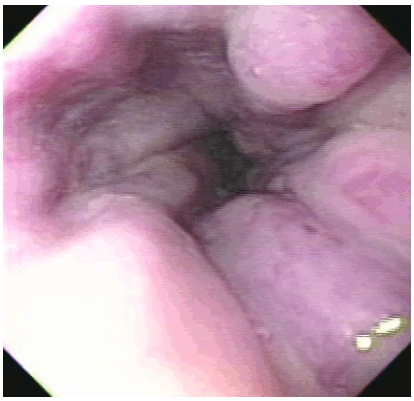

Figure 10. Esophageal varices in the lower esophagus in a child who presented with hematemesis. This child had cirrhosis associated with long-term parenteral nutrition use.

Figure 11. Foreign body (a piece of plastic) was found in the descending colon of this child with IF who presented with rectal bleeding.